

# Can uterine artery embolization be an alternative to plastic and reconstructive uterus operation by minimally invasive surgery?

## Kann die Uterusarterienembolisation eine Alternative zur plastischen und rekonstruktiven Gebärmutteroperation durch minimalinvasive Chirurgie sein?

### Abstract

**Introduction:** Plastic and reconstructive minimally invasive surgery has been established as gold standard in myomectomy. Therapy failure eventually leads to future surgical interventions or hysterectomy: surgeons and patients should be aware of the risks and benefits. We conducted a systematic review to analyse the evidence on the therapeutic indications and adverse events associated with uterine artery embolization and thereby evaluating if this method could be a valid alternative therapy.

**Methods:** In concordance with PRISMA guidelines, literature research was made in PubMed, Cochrane Library, UpToDate, Amboss and Medline databases. Clinical trials, reviews and case reports published in English between January 2010 and June 2020 were included.

**Results:** 44 articles were included out of 838 papers identified at initial search. Regarding uterine fibroids, three original papers and one Cochrane review reported the benefits of the procedure as an alternative to surgery, even in large and giant fibroids. Furthermore, several studies discussed the use of embolization for postpartum haemorrhage to decrease rates of hysterectomy after other haemostatic methods were exhausted, because of the potential risk of abnormal placentation in a future pregnancy. The procedure can also be successfully used as prophylactic method in different obstetrical procedures.

**Conclusions:** The use of embolization in different uterine pathologies is a minimally invasive procedure as an alternative to surgery, especially in women who desire to preserve their uterus. Its related complications are described and can be avoided by a stringent indication of the procedure. More evidence regarding fertility after UAE, use of the procedure prophylactically in obstetrical haemorrhage or in adenomyosis is needed.

**Keywords:** uterine artery embolization, myoma, complications, gynaecologic surgical procedures, haemostatic techniques

### Zusammenfassung

**Einleitung:** Die plastische und rekonstruktive minimal-invasive Chirurgie hat sich als Goldstandard in der Myomektomie etabliert. Therapieversagen führt schließlich zu weiteren chirurgischen Eingriffen oder zur Hysterektomie: Chirurgen und Patientinnen sollten sich der Risiken und des Nutzens bewusst sein. Wir führten eine systematische Übersichtsarbeit durch, um die Evidenz zu den therapeutischen Indikationen und unerwünschten Ereignissen im Zusammenhang mit der Uterusarterienembolisation zu analysieren und damit zu bewerten, ob diese Methode eine valide Therapiealternative darstellen könnte.

Cristina Cezar<sup>1</sup>

Luz Angela Torres de la Roche<sup>1</sup>

Jörg Hennefründ<sup>2</sup>

Hugo Christian Verhoeven<sup>3</sup>

Rajesh Devassy<sup>1</sup>

Rudy Leon De Wilde<sup>1</sup>

Working Group on Minimally Invasive Therapy in Benign Disease of the Uterine Wall (European Society of Gynecological Endoscopy, ESGE)

1 University Hospital for Gynecology, Pius Hospital, Carl von Ossietzky University Oldenburg, Germany

2 Tagesklinik Oldenburg, Germany

3 Private Center for Endocrinology, Preventive Medicine, Reproductive Medicine and Gynecology, Dusseldorf, Germany

**Methoden:** In Übereinstimmung mit dem PRISMA Leitfadens recherchierten wir die medizinische Literatur in den Datenbanken PubMed, Cochrane Library, UpToDate, Amboss und Medline. Klinische Studien, Reviews und Case Reports, die zwischen Januar 2010 und Juni 2020 in Englisch veröffentlicht wurden, waren einbezogen.

**Ergebnisse:** Von den 838 bei der ersten Suche identifizierten Arbeiten wurden 44 Artikel eingeschlossen. In Bezug auf Uterusmyome berichteten drei Originalarbeiten und ein Cochrane-Review über die Vorteile des Verfahrens als Alternative zur Operation, auch bei großen und riesigen Myomen. Darüber hinaus wurde in mehreren Studien der Einsatz der Embolisation bei postpartalen Blutungen diskutiert, um die Rate der Hysterektomie zu senken, nachdem andere hämostatische Methoden wegen des potentiellen Risikos einer abnormalen Plazentation in einer zukünftigen Schwangerschaft ausgeschöpft waren. Das Verfahren kann auch erfolgreich als prophylaktische Methode bei verschiedenen geburtshilflichen Eingriffen eingesetzt werden.

**Schlussfolgerungen:** Die Anwendung der Embolisation bei verschiedenen uterinen Pathologien ist ein minimal-invasives Verfahren als Alternative zur Operation, insbesondere bei Frauen, die ihren Uterus erhalten möchten. Die damit verbundenen Komplikationen sind beschrieben und können durch eine stringente Indikationsstellung des Verfahrens vermieden werden. Mehr Evidenz bezüglich der Fertilität nach UAE, des prophylaktischen Einsatzes des Verfahrens bei geburtshilflichen Blutungen oder bei Adenomyose ist erforderlich.

**Schlüsselwörter:** Uterusarterienembolisation, Myom, Komplikationen, gynäkologische chirurgische Eingriffe, hämostatische Techniken

## Introduction

Gold standard of care in myomectomy is the plastic and reconstructive minimally invasive uterine surgery [1]. The benefits of uterine artery embolization (UAE) in the treatment of different uterine pathologies are demonstrated for women desiring organ preservation, being minimally invasive, even in the treatment of giant fibroids [2]. Since its introduction in 1995 as conservative therapy for fibroids [3], the intervention has been developed, being applied for uterine pathologies such as myoma [4], postpartum haemorrhage (PPH) [5], or as a prophylactic procedure before obstetrical surgery with a high risk of massive bleeding [6], adenomyosis [7], and uterine vascular malformation [8]. However complications are possible [9], [10], which may increase the likelihood of therapy failure eventually leading to future surgical interventions [11].

## Material and methods

This review was performed according to the PRISMA guidelines [12]. In addition to clinical trials, we also analysed several case reports and case series in order to collect as much information as possible regarding the whole spectrum of complications. The research was performed using PubMed, Cochrane Library, UpToDate, Amboss and Medline databases, limited to articles published between January 2010 and June 2020. The search term combination consisted of words and words variations

for “uterine artery embolization”, “indications”, “major complications” and “minor complications”. Only articles published in English were selected. Exclusion criteria were: associated pathology as risk factors for venous thrombosis such as postpartum period, bed rest, blood transfusion, pelvic varicose veins and inherited thrombophilia, studies focused on technical aspects, earlier studies – EMMY trial 2006, FIBROID 2005, 2008, REST 2007 and also other minimally invasive procedure such as LUAO (laparoscopic uterine artery occlusion) – MARA 2012 study. Letters and editorials were also excluded.

## Results

Our initial database search identified a total of 838 records (n=178 for indications and n=660 for complications). After the duplicates were removed, 734 records remained and were further screened independently by the first two authors. The screening excluded 418 papers which were irrelevant to the topic of our review, discussing other aspects beside indications and outcomes of UAE. 71 further records were excluded, due to no full text availability. Out of 254 eligible articles, 210 were excluded according to our exclusion criteria: a total of 44 articles were eligible and included in this review (Figure 1).

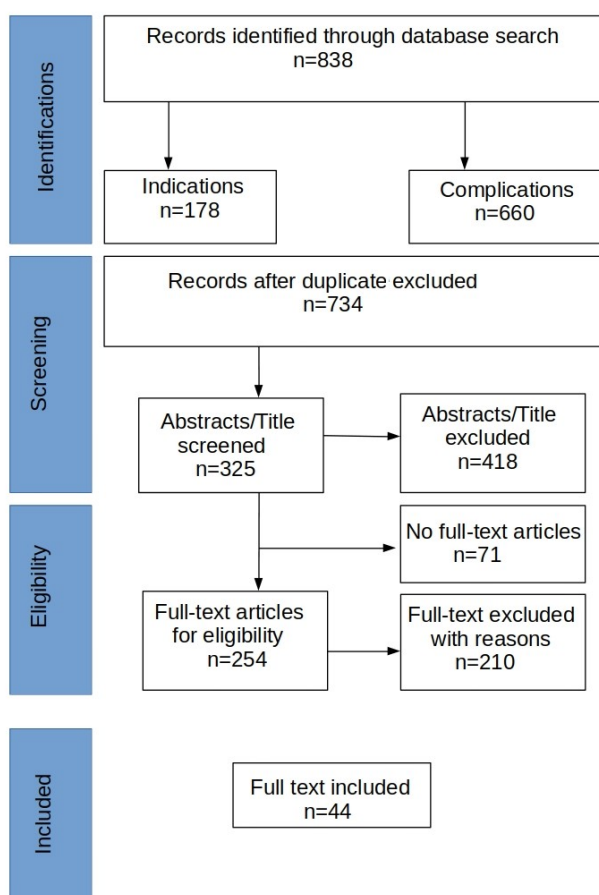


Figure 1: PRISMA flow chart of the reports selection

## Indications of UAE

### Uterine fibroids

Most of the studies included in our review discussed the use of UAE as an important tool in the treatment of myomas. The procedure proved to be an effective therapy for uterine fibroids in women with heavy menstrual bleeding who were resistant to other conservative therapies [13] and proposed as an alternative myoma therapy in women wishing to preserve fertility. However, the outcomes on fertility are still unclear [14].

The procedure can be performed irrespective of the number of fibroids and of their uterine location (submucosal, intramural or subserosal) [4]. Pedunculated fibroids are a relative contraindication of UAE, due to the risk of degeneration and subsequent infection which may lead to more or less severe complications [15], [16].

Three original papers REST 2011 [11], FUME 2012 [17], EMMY 2016 [18], and one Cochrane review studied the effects of UAE versus surgery, either myomectomy or hysterectomy, which we included (Table 1).

The REST 2011 study (Randomised comparison of uterine artery embolization with surgical treatment in patients with symptomatic uterine fibroids) compared the results of UAE versus surgery (myomectomy and hysterectomy) in 157 women with symptomatic fibroids. The study was multicentric, used a randomization 2:1 (106 UAE and

51 surgery) and a long follow-up of 5 years [11]. The improvement in quality of life was similar in both groups, with most complications occurring in the first 12 months; the authors concluded that the safety profile of UAE is equivalent to that of surgery. Even if the rate of reintervention was higher in the UAE group, it remained an alternative to surgery [11].

The FUME 2012 study (Fibroids of the Uterus: Myomectomy versus Embolization) compared the quality of life in patients following UAE or myomectomy performed for uterine fibroids in a prospective cohort [17]. The outcomes during a follow-up period of 5 years showed similar results regarding significant improvement in quality of life, but myomectomy remained more robust as procedure with fewer reinterventions and complications [17].

The EMMY 2016 study (Embolization vs. Hysterectomy) was a multicentric randomized controlled trial conducted between 2002 and 2004 which included 177 patients with symptomatic uterine fibroids who were treated either conservatively, UAE, or operatively by hysterectomy [18]. The study population was randomized to 81 UAE and 75 hysterectomies with the goal of comparing the outcomes and quality of life 10 years after the procedure [18], [19]. The authors concluded that every woman with symptomatic fibroids could be counselled about UAE as an alternative to hysterectomy, given that in 69% of cases a hysterectomy was avoided, and the satisfaction rates did not differ in both groups [18].

According to a Cochrane Review in 2014 [20], UAE remains a good alternative for the treatment of uterine fibroids, compared to surgical methods like myomectomy or hysterectomy, as it is associated with a shorter hospital stay and quicker recovery and is also rarely associated with the need of blood transfusion [20]. However it was observed that UAE was associated with more complications, but a direct correlation to major complications was inconclusive [20].

### UAE to improve fertility

Regarding the use of UAE to improve fertility in women with fibroids, Karlsen et al. [21] analysed the results of 17 studies including 989 patients. The authors observed that in women receiving UAE the rates of pregnancy were lower and the rates of miscarriage were higher, when compared to those with myomectomy. However, they also discussed the low quality of evidence, indicating the necessity of further studies to elucidate this aspect [21] (Table 2).

The effects of UAE on ovarian reserve is a subject of interest for clinicians and the results from different studies seem to indicate a negative influence of the procedure on ovarian reserve, however, the authors underlined the necessity of further studies to verify these outcomes [8]. The age of the patients plays an important role, with younger women having a decreased risk of ovarian failure after UAE [22]. Another approach to improve fertility in women with large fibroids could be the combination of UAE followed by myomectomy [23], [24].

**Table 1: Uterine artery embolization (UAE) versus surgery (myomectomy and/or hysterectomy) in the treatment of fibroids**

Reference	Design	Indication UAE	Outcomes	Conclusions
Moss et al. 2011 [11]	REST trial – prospective 2:1 randomized multi-centre, <i>UAE (n=106) vs. surgery (n=51)</i>	UAE for symptomatic fibroids vs. surgery (myomectomy and hysterectomy)	<ul style="list-style-type: none"> <li>• Similar results in improving quality of life (p=0.45)</li> <li>• Similar rates of adverse events 19% embolization and 25% surgery, p=0.40</li> <li>• Cumulative risk for re-intervention over 5 year higher in UAE group 32% compared to 4% surgery arm</li> </ul>	Benefits of UAE should be balanced against the need of re-intervention
Manyonda et al. 2012 [17]	FUME study – large prospective comparative study, <i>UAE (n=82) vs. myomectomy (n=81)</i>	UAE vs. myomectomy for fibroids	<ul style="list-style-type: none"> <li>• Similar results for improving the quality of life:                             <ul style="list-style-type: none"> <li>• symptom severity: p=0.13</li> <li>• concern: p=0.41</li> <li>• activities: p=0.21</li> <li>• mood: p=0.55</li> <li>• control: p=0.2</li> <li>• self-control: p=0.34</li> <li>• sex function: p=0.09</li> <li>• HRQL: p=0.14</li> </ul> </li> <li>• Complications:                             <ul style="list-style-type: none"> <li>• Minor complications: UAE 13.2% and surgery 10.9%, p=0.4</li> <li>• Major complications: UAE 2.9% and surgery 8%, p=0.28</li> </ul> </li> </ul>	Major limitation of the study: the lack of MR
De Bruijn et al. 2016 [18]	EMMY trial – large prospective randomized multi-centre controlled study, <i>UAE (n=81) vs. hysterectomy (n=75)</i>	UAE vs. hysterectomy for fibroids	<ul style="list-style-type: none"> <li>• Generic HRQOL at 10 years improved in both groups, p&lt;0.001</li> <li>• In about two thirds of UAE treated patients a hysterectomy can be avoided</li> </ul>	Counsel of eligible patients

UAE: uterine artery embolization  
 HRQL: health related quality of life  
 HRQOL: health reported quality of life

**Table 2: Fertility after uterine artery embolization for fibroids**

Reference	Design	Indication UAE	Outcomes
Karlsen et al. 2018 [21]	Systematic review on 17 studies (989 patients)	UAE for fibroids to improve fertility	<ul style="list-style-type: none"> <li>• Pregnancy rate lower (50% in UAE vs. 78% in myomectomy)</li> <li>• Miscarriage rate higher after UAE (60%) compared to myomectomy (20%)</li> </ul>
McLucas et al. 2016 [22]	Systematic review	UAE for fibroids to improve fertility	UAE is a valid but not perfect alternative of myomectomy

Table 3: Uterine artery embolization for large and very large fibroids

Reference	Design	Indication UAE	Outcomes	How to avoid complication/notes
Acharya et al. 2012 [26]	Case report	UAE for large fibroid uterus	Perforation of the transverse colon – catastrophic complication	MR needed for the morphology of fibroids
Peters et al. 2017 [27]	Case report	UAE for fibroids	Toxic megacolon near to perforation	Differentiation PES from infection and ischaemia
Martins et al. 2016 [28]	Case report	UAE for fibroids	Expulsion of infarcted myoma and uterine sepsis	MR selection of patients
Obele et al. 2016 [29]	Case report	UAE for fibroids	Pyomyoma, uterine sepsis	Resolved by supracervical hysterectomy
Bérczi et al. 2015 [31]	Retrospective comparative study, <i>n=303 UAE – small fibroids &lt;10 cm (n=262) vs. large fibroids &gt;10 cm (n=41)</i>	UAE for fibroids	No significant differences between groups regarding safety (minor and major complications): <ul style="list-style-type: none"> <li>• fever p=0.063</li> <li>• temporary amenorrhoea p=1.0</li> <li>• prolonged menstruation p=1.0</li> <li>• aspecific infection p=0.354</li> <li>• postprocedural dysmenorrhoea p=0.550</li> <li>• intermittent menorrhagia p=0.519</li> <li>• myoma expulsion p=0.519</li> <li>• elective myomectomy90 p=0.0</li> <li>• acute hysterectomy p=0.253</li> </ul>	UAE can be offered for women with large fibroids

PES: postembolization syndrome  
UAE: uterine artery embolization

### UAE in large and very large fibroids

Regarding the size of the fibroids to be treated, previous trials have demonstrated a low evidence (level 1) [2] in the use of UAE as treatment of most fibroid sizes [11], [18].

The effectiveness and safety of UAE in the treatment of large and very large fibroids have been debated [2]: we found one retrospective study [25] and four case reports [26], [27], [28], [29] (Table 3) indicating a higher risk of complications such as uterine necrosis and infection, possible leading to sepsis and necessity of hysterectomy, or even life threatening situations due to ischemia of adjacent organs such as toxic megacolon or perforation of transverse colon [26].

Regarding the issue of large fibroids, a new report discussed the possibility of the aberrant vascularization of large fibroids from neighbouring abdominal structures, a situation which requires a better consideration of cases to be embolized [30]. In this report, 24 cases of large fibroids treated between 2008 and 2017 were analysed. In all subjects, arteriography and embolization were performed prior to subsequent myomectomy or total hysterectomy. In three cases the arteriography showed the aberrant vascularization of the large fibroids from omental arteries and gastroepiploic arteries [30]. However, this kind of complications are rare [31], [30]. Concerning the safety and effectiveness of UAE in fibroids larger than

10 cm, Bérczi et al. reported the results of 303 patients underlying no differences observed between fibroids smaller and larger than 10 cm [29].

### UAE prophylactic use in obstetrical procedures and postpartum haemorrhage

A further useful indication of UAE is as a prophylactic method before obstetrical procedures with high risk of massive bleeding such as dilatation and curettage associated with uterine ectopic pregnancy (cervical or caesarean scar) [6], termination of pregnancy with complete placenta praevia (CPP) [32], [33], suspected gestational trophoblastic disease, or retained placenta with vascularity [5], [6] (Table 4).

Concerning the effects on future pregnancy, different authors reported that UAE might induce endometrial ischemia and necrosis, potentially followed by abnormal placentation, with afterwards affected uteroplacental exchange and possible intrauterine growth restriction [23], placenta accrete [34], [35], placenta increta [36], and placenta praevia [37]. The leading factors which contribute to necrosis are reduced blood flow as well as damage to the endomyometrium [38].

Other previous studies and trials have documented that several procedures to control the bleeding such as uterine compression sutures (B-Lynch) or Bakri balloon tamponade have to be taken into consideration by clinicians be-

Table 4: Uterine artery embolization before obstetrical procedures and for postpartum haemorrhage

Reference	Design	Indication UAE	Outcomes	Conclusions
Ko et al. 2017 [6]	Retrospective descriptive study on 29 patients	Prophylactic UAE for obstetrical procedures to avoid massive bleeding	Safe and effective, especially when preservation of fertility is wished	Prospective randomized studies needed to confirm the results
Wang et al. 2018 [33]	Case report	UAE-assisted induction of labor for pregnancy termination in CPP and anencephaly	Sepsis – rare, but serious	Septic shock, emergency caesarean section with intravenous antibiotics – well recovered
Peng et al. 2015 [32]	Prospective study, n=47	UAE-assisted induction of labor for pregnancy termination	Feasible method in reducing postpartum hemorrhage	Short term adverse effects should be noted
Huang et al. 2015 [55]	Retrospective study, n=7	UAE-assisted induction of labor in placenta previa to avoid caesarean section	1 femoral artery thrombosis, 2 infections	All complications well recovered
Jitsumori et al. 2020 [5]	Retrospective study, n=3155 (post UAE group n=16, non UAE n=3139)	UAE for PPH	Risk of PAS investigated: significantly more cases in the post UAE (37.5%) vs. non UAE (1.2%) OR, 50.303; 95% CI, 17.38 to 145.592; p<0.01	UAE is a significant risk factor for PAS – hysterectomy needed due to placenta accreta

UAE: uterine artery embolization  
 CPP: complete placenta praevia  
 PPH: postpartum haemorrhage  
 PAS: placenta accreta subsequent

fore proceeding to embolization, as these haemostatic methods seem not to be associated with increased risk of abnormal placentation [39], [40], [41], [42].

### UAE for adenomyosis

Concerning the use of UAE, a recent review reports a good level of evidence regarding the acceptance and safety of the procedure, but the evidence is low regarding fertility outcomes after the procedure [7], [43].

### Complications of the UAE

In defining the complications of UAE several criteria and classifications are used [4], [11], [23], [28]. According to SIR (Society of Interventional Radiology), the complications of UAE can be divided in five grades [11], the first two categories being considered as minor and the other three as major complications.

1. No therapy, no consequence.
2. No therapy, no consequence, but including overnight observation.
3. Therapy needed, short hospitalization <48 hours.
4. Major therapy needed, prolonged hospitalisation >48 hours.
5. Permanent sequelae for the patient [44].

Depending on the moment of onset, the complications can be divided into acute, subacute and chronic [4]:

1. Acute (in the first 24 hours after UAE): such as PES – post embolization syndrome, septic bleeding, pulmonary embolus, vasovagal response [45].
2. Subacute (up to one week) and chronic: urinary retention, local infections such as endometritis or abscesses, amenorrhea, necrosis, fibroid expulsion [13].

Classifications regarding the intensity of the events:

#### 1. Minor complications [28]

- Post-embolization syndrome (PES) induced by an inflammatory response to the necrotic tissue and characterized by fever, nausea and vomiting, local pain and leukocytosis [46].
- Fibroid passage [47] after UAE with severe menstrual cramping, vaginal discharge, sometimes fibroid expulsion or even severe bleeding [28].

#### 2. Major complications [23]

- Events related to technical procedure: iodine allergy, vessel dissection or aneurysm, arterial thrombosis or pulmonary embolism.
- Ischemic necrotic complications which could be limited to genital area or at distance due to the passage of embolizing particles into vessels.
- Infection: puncture site infections, up to severe forms such as provoked endometritis and sepsis.
- Death by large pulmonary embolus or sepsis with multiorgan system failure, due to uterine necrosis.

Another important aspect to be taken into account is the risk of repeated UAE and reintervention. According to the REST trial [11], the rates of reinterventions were 13% at 1 year to 32% at 5 years, compared to 2% in organ saving surgery at 1 and 5 years [47].

UAE complications' incidence:

- Prolonged vaginal discharge 2–17% [47]
- Discharge with fever 4% [47]
- UAE failure 4% [47]
- Urinary stress incontinence 3.7%, pressure symptoms 2.8% or menorrhagia 2.6% [47]
- Postembolization syndrome 2.86% [47]
- Fibroid expulsion 1–10% [48], [49], [50], [51] ranging up to 50% for submucosal fibroids [52]. A cervical passage of fibroids can occur even 3 years after the procedure has been done [53]. The submucosal and intracavitary location of the fibroids is more frequently associated with the expulsion which could lead to a septic complication [28]. Therefore, preprocedural MR was proposed to localize the myoma and thereby improve the outcomes of the intervention performed on selected patients [28].
- Septicaemia 1–3% [47]
- Pulmonary embolization <1% or deep vein thrombosis <1% [47]
- Rare complications at the urinary bladder as vesical fissure <1% or intra-abdominal abscess <1% [47]
- Permanent amenorrhoea 0–3% under 45 years and 20–40% in older women [54]
- Less common complications such as infectious events and even septic reactions due to the material used or injuries of nerves and vessels [48]
- Patients requiring hysterectomy due to the complications <1% [48]

## Discussion

The present paper summarizes the current publications regarding the indications and complications of UAE in different uterine pathologies. Despite the large heterogeneity of the reports and reviews presented, there is a trend to consider UAE as an alternative therapy, as the major complications are rare, sustained by the previous metaanalysis [10]. Several papers described serious and severe complications especially when UAE was performed in large fibroids [2], [26], [27], [28], [29]; these complications may be avoided by stringent indication of the intervention after preprocedural imaging such as MRI or even CT [30], [47].

As an approach to treat postpartum haemorrhage, UAE has been used as a prophylactic method in high-risk patients before different abortive procedures to avoid massive bleeding, to decrease rates of hysterectomy [6]. Because of the risk of subsequent placenta accreta in future pregnancies, clinicians should consider standard methods to stop massive bleeding before proceeding to embolization [39], [40], [41], [42]. Cases should be made on an individual basis and discussed with the patient before establishing a therapeutic plan as shared consent. The strength of this work is the extensive incorporation of research published since 2010, including case reports and case series up to clinical trials and studies. A limitation of this review is that only articles published in English language were taken into consideration, eventually excluding other relevant articles reported in other languages. In addition, the heterogeneity in the definition of major and minor complications within studies limited the qualitative analysis.

Despite the limitations, the actual trend useful for the clinicians as much as for the patients is to consider UAE as a tool to treat women with different uterine pathologies. UAE showed acceptable clinical outcomes in the treatment of uterine myomata, even in the management of fibroids larger than 10 cm. However, due to the risk of possible complications, imaging such as MR or CT is advised to be performed before the procedure. Complications are possible, so these problems should be discussed with the patient before establishing a therapeutic plan.

## Conclusion

Current data show that UAE is an acceptable procedure to treat different uterine pathologies. However, several trials and studies discuss the high risk of complications and reinterventions, emphasizing the importance of proper selection of women that could benefit from the procedure. Patients with various symptomatic uterine pathologies can be counselled about the possibility of UAE as an alternative to surgery such as myomectomy or hysterectomy.

Regarding future research, several aspects have to be clarified such as fertility after UAE, the use of the procedure in obstetrical haemorrhage, in adenomyosis, and

eventually comparing it with other minimally invasive treatment by means of high frequency ultrasound using newly designed prospective randomized controlled studies.

## Notes

## Competing interests

The authors declare that they have no competing interests.

## Authors' contributions

RDW, CC and LATR: conceptualization. CC and LATR: data curation, formal analysis, writing original study report. All authors read, corrected and approved the final manuscript, based on their expertise.

## Acknowledgments

Jennifer Eidswick for language corrections.

## References

- Hirschelmann A, De Wilde RL. Plastic and reconstructive uterus operations by minimally invasive surgery? A review on myomectomy. *GMS Interdiscip Plast Reconstr Surg DGPW*. 2012 Jan 9;1:Doc09. DOI: 10.3205/ipsr000009
- Llewellyn O, Patel NR, Mallon D, Quinn SD, Hamady M. Uterine Artery Embolisation for Women with Giant Versus Non-giant Uterine Fibroids: A Systematic Review and Meta-analysis. *Cardiovasc Intervent Radiol*. 2020 May;43(5):684-93. DOI: 10.1007/s00270-019-02359-7
- Ravina JH, Herbreteau D, Ciraru-Vigneron N, Bouret JM, Houdart E, Aymard A, Merland JJ. Arterial embolisation to treat uterine myomata. *The Lancet*. 1995 Sep 9(346):671-2. DOI: 10.1016/s0140-6736(95)92282-2
- Masciocchi C, Arrigoni F, Ferrari F, Giordano AV, Iafrate S, Capretti I, Cannizzaro E, Reginelli A, Ierardi AM, Floridi C, Angileri AS, Brunese L, Barile A. Uterine fibroid therapy using interventional radiology mini-invasive treatments: current perspective. *Med Oncol*. 2017 Apr;34(4):52. DOI: 10.1007/s12032-017-0906-5
- Jitsumori M, Matsuzaki S, Endo M, Hara T, Tomimatsu T, Matsuzaki S, Miyake T, Takiuchi T, Kakigano A, Mimura K, Kobayashi E, Ueda Y, Kimura T. Obstetric Outcomes of Pregnancy After Uterine Artery Embolization. *Int J Womens Health*. 2020;12:151-8. DOI: 10.2147/IJWH.S236443
- Ko HK, Shin JH, Ko GY, Gwon DI, Kim JH, Han K, Lee SW. Efficacy of Prophylactic Uterine Artery Embolization before Obstetrical Procedures with High Risk for Massive Bleeding. *Korean J Radiol*. 2017 Mar-Apr;18(2):355-60. DOI: 10.3348/kjr.2017.18.2.355
- Dessouky R, Gamil SA, Nada MG, Mousa R, Libda Y. Management of uterine adenomyosis: current trends and uterine artery embolization as a potential alternative to hysterectomy. *Insights Imaging*. 2019 Apr;10(1):48. DOI: 10.1186/s13244-019-0732-8
- El Shamy T, Amer SAK, Mohamed AA, James C, Jayaprakasan K. The impact of uterine artery embolization on ovarian reserve: A systematic review and meta-analysis. *Acta Obstet Gynecol Scand*. 2020 Jan;99(1):16-23. DOI: 10.1111/aogs.13698
- Edwards RD, Moss JG, Lumsden MA, Wu O, Murray LS, Twaddle S, Murray GD; Committee of the Randomized Trial of Embolization versus Surgical Treatment for Fibroids. Uterine-artery embolization versus surgery for symptomatic uterine fibroids. *N Engl J Med*. 2007 Jan;356(4):360-70. DOI: 10.1056/NEJMoa062003
- Toor SS, Jaber A, Macdonald DB, McInnes MD, Schweitzer ME, Rasuli P. Complication rates and effectiveness of uterine artery embolization in the treatment of symptomatic leiomyomas: a systematic review and meta-analysis. *AJR Am J Roentgenol*. 2012 Nov;199(5):1153-63. DOI: 10.2214/AJR.11.8362
- Moss JG, Cooper KG, Khaund A, Murray LS, Murray GD, Wu O, Craig LE, Lumsden MA. Randomised comparison of uterine artery embolisation (UAE) with surgical treatment in patients with symptomatic uterine fibroids (REST trial): 5-year results. *BJOG*. 2011 Jul;118(8):936-44. DOI: 10.1111/j.1471-0528.2011.02952.x
- Moher D, Liberati A, Tetzlaff J, Altman DG; PRISMA Group. Preferred reporting items for systematic reviews and meta-analyses: the PRISMA statement. *PLoS Med*. 2009 Jul;6(7):e1000097. DOI: 10.1371/journal.pmed.1000097
- Memtsa M, Homer H. Complications associated with uterine artery embolisation for fibroids. *Obstet Gynecol Int*. 2012;2012:290542. DOI: 10.1155/2012/290542
- Torre A, Paillusson B, Fain V, Labauge P, Pelage JP, Fauconnier A. Uterine artery embolization for severe symptomatic fibroids: effects on fertility and symptoms. *Hum Reprod*. 2014 Mar;29(3):490-501. DOI: 10.1093/humrep/det459
- Kido A, Ascher SM, Kishimoto K, Hahn W, Jha RC, Togashi K, Spies JB. Comparison of uterine peristalsis before and after uterine artery embolization at 3-T MRI. *AJR Am J Roentgenol*. 2011 Jun;196(6):1431-5. DOI: 10.2214/AJR.10.5349
- Bulman JC, Ascher SM, Spies JB. Current concepts in uterine fibroid embolization. *Radiographics*. 2012 Oct;32(6):1735-50. DOI: 10.1148/rg.326125514
- Manyonda IT, Bratby M, Horst JS, Banu N, Gorti M, Belli AM. Uterine artery embolization versus myomectomy: impact on quality of life – results of the FUME (Fibroids of the Uterus: Myomectomy versus Embolization) Trial. *Cardiovasc Intervent Radiol*. 2012 Jun;35(3):530-6. DOI: 10.1007/s00270-011-0228-5
- de Bruijn AM, Ankum WM, Reekers JA, Birnie E, van der Kooij SM, Volkers NA, Hehenkamp WJ. Uterine artery embolization vs hysterectomy in the treatment of symptomatic uterine fibroids: 10-year outcomes from the randomized EMMY trial. *Am J Obstet Gynecol*. 2016 Dec;215(6):745.e1-745.e12. DOI: 10.1016/j.ajog.2016.06.051
- van der Kooij SM, Hehenkamp WJ, Volkers NA, Birnie E, Ankum WM, Reekers JA. Uterine artery embolization vs hysterectomy in the treatment of symptomatic uterine fibroids: 5-year outcome from the randomized EMMY trial. *Am J Obstet Gynecol*. 2010 Aug;203(2):105.e1-13. DOI: 10.1016/j.ajog.2010.01.049
- Gupta JK, Sinha A, Lumsden MA, Hickey M. Uterine artery embolization for symptomatic uterine fibroids. *Cochrane Database Syst Rev*. 2014 Dec;(12):CD005073. DOI: 10.1002/14651858.CD005073.pub4
- Karlsen K, Hrobjartsson A, Korsholm M, Mogensen O, Humaidan P, Ravn P. Fertility after uterine artery embolization of fibroids: a systematic review. *Arch Gynecol Obstet*. 2018 Jan;297(1):13-25. DOI: 10.1007/s00404-017-4566-7
- McLucas B, Voorhees WD 3rd, Elliott S. Fertility after uterine artery embolization: a review. *Minim Invasive Ther Allied Technol*. 2016;25(1):1-7. DOI: 10.3109/13645706.2015.1074082



23. Soro MP, Denys A, de Rham M, Baud D. Short & long term adverse outcomes after arterial embolisation for the treatment of postpartum haemorrhage: a systematic review. *Eur Radiol*. 2017 Feb;27(2):749-62. DOI: 10.1007/s00330-016-4395-2
24. Madhuri TK, Kamran W, Walker W, Butler-Manuel S. Synchronous uterine artery embolization and laparoscopic myomectomy for massive uterine leiomyomas. *JLS*. 2010 Jan-Mar;14(1):120-2. DOI: 10.4293/108680810X12674612015021
25. Pelage JP, Le Dref O, Soyer P, Kardache M, Dahan H, Abitbol M, Merland JJ, Ravina JH, Rymer R. Fibroid-related menorrhagia: treatment with superselective embolization of the uterine arteries and midterm follow-up. *Radiology*. 2000 May;215(2):428-31. DOI: 10.1148/radiology.215.2.r00ma11428
26. Acharya J, Bancroft K, Lay J. Perforation of transverse colon: a catastrophic complication of uterine artery embolization for fibroids. *Cardiovasc Intervent Radiol*. 2012 Dec;35(6):1524-7. DOI: 10.1007/s00270-012-0349-5
27. Peters S, Wise M, Buckley B. An unexpected complication following uterine artery embolisation. *BMJ Case Rep*. 2017 Sep;2017. pii: bcr2016217238. DOI: 10.1136/bcr-2016-217238
28. Martins JG, Gaudenti D, Crespo F, Ganesh D, Verma U. Uncommon Complication of Uterine Artery Embolization: Expulsion of Infarcted Myoma and Uterine Sepsis. *Case Rep Obstet Gynecol*. 2016;2016:8695318. DOI: 10.1155/2016/8695318
29. Obele CC, Dunham S, Bennett G, Pagan J, Sung LY, Charles HW. A Case of Pyomyoma following Uterine Fibroid Embolization and a Review of the Literature. *Case Rep Obstet Gynecol*. 2016;2016:9835412. DOI: 10.1155/2016/9835412
30. Anton K, Rosenblum NG, Teefey P, Dayaratna S, Gonsalves CF. The Enlarged Fibroid Uterus: Aberrant Arterial Supply via the Omental Artery. *Cardiovasc Intervent Radiol*. 2019 Apr;42(4):615-9. DOI: 10.1007/s00270-018-2087-9
31. Bérczi V, Valcseva É, Kozics D, Kalina I, Kaposi P, Sziller P, Várbiro S, Botos EM. Safety and Effectiveness of UFE in Fibroids Larger than 10 cm. *Cardiovasc Intervent Radiol*. 2015 Oct;38(5):1152-6. DOI: 10.1007/s00270-014-1045-4
32. Peng Q, Zhang W. Uterine arterial embolization to assist induction of labor among patients with complete placenta previa. *Int J Gynaecol Obstet*. 2015 Aug;130(2):132-6. DOI: 10.1016/j.ijgo.2015.02.033
33. Wang Y, Huang X. Sepsis after uterine artery embolization-assisted termination of pregnancy with complete placenta previa: A case report. *J Int Med Res*. 2018 Jan;46(1):546-50. DOI: 10.1177/0300060517723257
34. Kanter G, Packard L, Sit AS. Placenta accreta in a patient with a history of uterine artery embolization for postpartum hemorrhage. *J Perinatol*. 2013 Jun;33(6):482-3. DOI: 10.1038/jp.2012.99
35. Poggi SH, Yaeger A, Wahdan Y, Ghidini A. Outcome of pregnancies after pelvic artery embolization for postpartum hemorrhage: retrospective cohort study. *Am J Obstet Gynecol*. 2015 Oct;213(4):576.e1-5. DOI: 10.1016/j.ajog.2015.06.063
36. Kitao K, Makihara N, Morita H, Yamasaki M, Matsuoka S, Ohara N, Maruo T. The development of placenta increta following pelvic transcatheter artery embolization for postpartum hemorrhage. *Clin Exp Obstet Gynecol*. 2009;36(1):53-4.
37. Igarashi S, Izuchi S, Ogawa Y, Yoshimathu M, Takizawa K, Nakajima Y, Tanaka M, Ishizuka B, Suzuki N. N-butyl cyanoacrylate is very effective for massive haemorrhage during the perinatal period. *PLoS One*. 2013;8(10):e77494. DOI: 10.1371/journal.pone.0077494
38. Poujade O, Ceccaldi PF, Davitian C, Amate P, Chatel P, Khater C, Aflak N, Vilgrain V, Luton D. Uterine necrosis following pelvic arterial embolization for post-partum hemorrhage: review of the literature. *Eur J Obstet Gynecol Reprod Biol*. 2013 Oct;170(2):309-14. DOI: 10.1016/j.ejogrb.2013.07.016
39. Nishikawa A, Matsuzaki S, Mimura K, Kanagawa T, Kimura T. Short interpregnancy interval after B-Lynch uterine compression suture: a case report. *Clin Exp Obstet Gynecol*. 2016;43(3):434-6.
40. Nagase Y, Matsuzaki S, Kawanishi Y, Nakagawa S, Kakigano A, Takiuchi T, Mimura K, Tomimatsu T, Endo M, Kimura T. Efficacy of Prophylactic Antibiotics in Bakri Intrauterine Balloon Placement: A Single-Center Retrospective Analysis and Literature Review. *AJP Rep*. 2020 Jan;10(1):e106-e112. DOI: 10.1055/s-0040-1708487
41. Matsuzaki S, Jitsumori M, Hara T, Matsuzaki S, Nakagawa S, Miyake T, Takiuchi T, Kakigano A, Kobayashi E, Tomimatsu T, Kimura T. Systematic review on the needle and suture types for uterine compression sutures: a literature review. *BMC Surg*. 2019 Dec;19(1):196. DOI: 10.1186/s12893-019-0660-z
42. Carlson L, Jackson C, Glover A, Webster G, Dotters-Katz S, Strauss R. Subsequent Pregnancy Outcomes Following Use of an Intrauterine Tamponade Balloon for Postpartum Hemorrhage (PPH). *Obstetrics & Gynecology*. 2017;129(5):36-7. DOI: 10.1097/01.AOG.0000514338.16396.61
43. de Bruijn AM, Lohle PN, Huirne JA, de Vries J, Twisk M; QUESTA-Trial Group; Hehenkamp WJ. Uterine Artery Embolization Versus Hysterectomy in the Treatment of Symptomatic Adenomyosis: Protocol for the Randomized QUESTA Trial. *JMIR Res Protoc*. 2018 Mar;7(3):e47. DOI: 10.2196/resprot.8512
44. Cardella JF, Kundu S, Miller DL, Millward SF, Sacks D; Society of Interventional Radiology. Society of Interventional Radiology clinical practice guidelines. *J Vasc Interv Radiol*. 2009 Jul;20(7 Suppl):S189-91. DOI: 10.1016/j.jvir.2009.04.035
45. Firouznia K, Ghanaati H, Jalali AH, Shakiba M. Uterine artery embolization for treatment of symptomatic fibroids: a review of the evidence. *Iran Red Crescent Med J*. 2013 Dec;15(12):e16699. DOI: 10.5812/ircmj.16699
46. Ubillus W, Munoz J, Vekaria M, Wollner I, Getzen T. Post-embolization syndrome: Outcomes regarding the type of embolization. *J Clin Oncol*. 2011 May;29(15):e14582. DOI: 10.1200/jco.2011.29.15\_suppl.e14582
47. Martin J, Bhanot K, Athreya S. Complications and reinterventions in uterine artery embolization for symptomatic uterine fibroids: a literature review and meta analysis. *Cardiovasc Intervent Radiol*. 2013 Apr;36(2):395-402. DOI: 10.1007/s00270-012-0505-y
48. Kohi MP, Spies JB. Updates on Uterine Artery Embolization. *Semin Intervent Radiol*. 2018 Mar;35(1):48-55. DOI: 10.1055/s-0038-1636521
49. Sanampudi S, Gabriel G, Hoffman M, Raissi D. Impending fibroid expulsion on MRI after uterine fibroid embolization. *Radiol Case Rep*. 2019 Jun;14(6):673-7. DOI: 10.1016/j.radcr.2019.03.011
50. Shlansky-Goldberg RD, Coryell L, Stavropoulos SW, Terrotola SO, Mondschein J, Beshara M, Butts SF, Sondheimer S, Tureck RW, Rosen M. Outcomes following fibroid expulsion after uterine artery embolization. *J Vasc Interv Radiol*. 2011 Nov;22(11):1586-93. DOI: 10.1016/j.jvir.2011.08.004
51. Silberzweig JE, Powell DK, Matsumoto AH, Spies JB. Management of Uterine Fibroids: A Focus on Uterine-sparing Interventional Techniques. *Radiology*. 2016 Sep;280(3):675-92. DOI: 10.1148/radiol.2016141693
52. Radeleff B, Eiers M, Bellemann N, Ramsauer S, Rimbach S, Kauczor HU, Richter GM. Expulsion of dominant submucosal fibroids after uterine artery embolization. *Eur J Radiol*. 2010 Jul;75(1):e57-63. DOI: 10.1016/j.ejrad.2009.07.013

53. Stott D, Zakaria M. The transcervical expulsion of a large fibroid. *BMJ Case Rep.* 2012 Sep;2012. pii: bcr0120125523. DOI: 10.1136/bcr.01.2012.5523
54. Dariushnia SR, Nikolic B, Stokes LS, Spies JB; Society of Interventional Radiology Standards of Practice Committee. Quality improvement guidelines for uterine artery embolization for symptomatic leiomyomata. *J Vasc Interv Radiol.* 2014 Nov;25(11):1737-47. DOI: 10.1016/j.jvir.2014.08.029
55. Huang L, Awale R, Tang H, Zeng Z, Li F, Chen Y. Uterine artery embolization, not cesarean section, as an option for termination of pregnancy in placenta previa. *Taiwan J Obstet Gynecol.* 2015 Apr;54(2):191-3. DOI: 10.1016/j.tjog.2014.04.028

**Please cite as**

Cezar C, Torres de la Roche LA, Hennefründ J, Verhoeven HC, Devassy R, De Wilde RL, Working Group on Minimally Invasive Therapy in Benign Disease of the Uterine Wall (European Society of Gynecological Endoscopy, ESGE). Can uterine artery embolization be an alternative to plastic and reconstructive uterus operation by minimally invasive surgery? *GMS Interdiscip Plast Reconstr Surg DGPW.* 2021;10:Doc07. DOI: 10.3205/iprs000157, URN: urn:nbn:de:0183-iprs0001579

**This article is freely available from**

<https://www.egms.de/en/journals/iprs/2021-10/iprs000157.shtml>

**Published:** 2021-06-09

**Copyright**

©2021 Cezar et al. This is an Open Access article distributed under the terms of the Creative Commons Attribution 4.0 License. See license information at <http://creativecommons.org/licenses/by/4.0/>.

**Corresponding author:**

Rajesh Devassy, MD  
University Hospital for Gynecology, Pius Hospital, Carl von Ossietzky University Oldenburg, Georgstrasse 12, 26121 Oldenburg, Germany, Phone: + 49 441 229 1500  
[rajeshdevassy@gmail.com](mailto:rajeshdevassy@gmail.com)